

AFRI
SCIENTIFIC
REPORT

1973


COMPARISON OF TECHNETIUM-99m POLYPHOSPHATE
AND STRONTIUM-85 FOR SKELETAL IMAGING
IN PATIENTS WITH METASTATIC DISEASE

J. S. STEVENSON
C. D. MAYNARD*

* Bowman Gray School of Medicine
Winston-Salem, North Carolina



JOE E. WEST
Lieutenant Colonel, USAF, VC
Chairman
Radiation Biology Department



MYRON I. VARON
Captain MC USN
Director

ARMED FORCES RADIOBIOLOGY RESEARCH INSTITUTE
Defense Nuclear Agency
Bethesda, Maryland

Approved for public release; distribution unlimited

ACKNOWLEDGMENT

The authors would like to thank the staff of the Department of Nuclear Medicine of the Bowman Gray School of Medicine for their technical assistance in obtaining some of the data used in preparing this report.

F

A

I

II

IV

R

Fi

Fi

Fi

Fi

Fig

Fig

TABLE OF CONTENTS

	Page
Foreword (No. technical summary)	iii
Abstract	iv
I. Introduction	1
Principle	1
Choice of radiopharmaceutical	2
Technetium-99m polyphosphate	3
II. Materials and Methods	4
III. Results and Discussion	6
IV. Summary	9
References	11

LIST OF FIGURES

Figure 1. Technetium-99m polyphosphate and strontium-85 bone scans depicting the interference from bladder activity obtained with the technetium-99m polyphosphate agent and bowel activity with the strontium-85 agent	5
Figure 2. Normal technetium-99m polyphosphate and strontium-85 bone scans	7
Figure 3. Anterior and posterior views in a normal technetium-99m polyphosphate bone scan	7
Figure 4. Bone scan obtained with technetium-99m polyphosphate revealing multiple metastatic lesions in a patient with metastasis from carcinoma of the breast	8
Figure 5. A technetium-99m polyphosphate bone scan and a strontium-85 bone scan obtained from a patient with metastatic lesions from carcinoma of the breast	8
Figure 6. Skull roentgenogram and technetium-99m polyphosphate bone scan in a patient with Paget's disease	9

FOREWORD
(Nontechnical summary)

A comparative study of 75 patients with known metastatic disease was done utilizing strontium-85 and technetium-99m polyphosphate radiopharmaceuticals for bone scanning. It was discovered that a greater number of lesions could be detected with the technetium-99m polyphosphate scan (approximately 20 percent of the patients) than with strontium-85 bone scans. The advantages of the technetium-99m polyphosphate scanning agent over strontium-85 included an increased counting rate, shorter scanning times, and ability to image on the same day of administration. The increased counting rate and shorter scanning times appeared to be due to the higher administrative dose which could be given with the technetium-99m polyphosphate agent. Technetium-99m polyphosphate also resulted in suitable imaging by either the scintillation camera or the rectilinear scanner. The absence of colon activity normally seen in strontium-85 scans was helpful, but the increased bladder activity obtained with technetium-99m required voiding prior to each scan. It appears that the ideal physical characteristics of technetium-99m polyphosphate for scanning and its increased sensitivity for detecting bone lesions make it a far superior radiopharmaceutical for skeletal imaging than strontium-85.

ABSTRACT

Technetium-99m polyphosphate has been recently introduced to replace strontium-85 as a short-lived radiopharmaceutical for skeletal imaging. Bone scans have been obtained with both strontium-85 and technetium-99m, to compare their relative efficacy, in a series of patients with known malignant disease. When possible, the same instrumentation was utilized with both radiopharmaceuticals in each patient. Data on approximately 75 patients indicate that the technetium-99m polyphosphate bone scans will detect a greater number of lesions than strontium-85, in approximately 20 percent of the patients. Other advantages of technetium-99m polyphosphate include: a greatly increased counting rate with shorter scanning time, the ability to image on the day of administration of the dose, suitability for imaging by either camera or scanner, absence of colon activity, and a greatly diminished radiation exposure to the patient. It is evident that technetium-99m polyphosphate is definitely superior to strontium-85 as a bone scanning agent.

ease,
for det
remain
strate
of the
to dem
double
earlier
L
tium ar
used to
Later,
radioac
tures.
in bone
1961, h
ning the
P
trauma,
turnove
apatite

I. INTRODUCTION

Bone involvement occurs frequently in patients with malignant neoplastic disease, and roentgenograms of the skeletal system have been one of the routine methods for detecting metastatic bone lesions, for many years, despite the fact that they may remain normal until late in the clinical course of the disease. It has been demonstrated that bone destruction does not appear on a roentgenogram until 30 - 50 percent of the calcium content has been removed.² Bone scanning, however, has been shown to demonstrate bone destruction when the rate of bone mineral turnover has been doubled;⁴ therefore, bone scanning has the potential to show bony metastases much earlier in the clinical course of the disease than roentgenograms.

In 1942, Treadwell et al.⁷ demonstrated the similarity of the handling of strontium and calcium by bone. It then became evident that radioactive tracers could be used to measure areas of active osteogenesis in both normal and diseased bone. Later, Bauer and Wendeberg¹ were successful in showing increased concentrations of radioactive strontium in bones damaged by malignant disease, infection, and fractures. In 1960, Gynning et al.⁵ found that the increased concentration of strontium-85 in bone lesions could be detected prior to routine bone x-ray changes. It was not until 1961, however, that Fleming et al.³ were able to demonstrate with scintillation scanning the increased accumulation of strontium-85 in bone.

Principle. Any bone destructive process, such as inflammation, tumor or trauma, stimulates the formation of reactive new bone and accelerates bone mineral turnover. The new bone begins as immature osteoid tissue containing a hydroxyapatite crystal. It is the interaction of radiopharmaceuticals such as strontium-85,

strontium-87m and fluorine-18 with these crystals that forms the basis of bone scanning. Radioactive tracers will accumulate in areas of active new bone formation to a greater extent than in the surrounding normal bone. When scanned they will show up as "hot" areas. Diseases that incite entirely destructive bone lesions (which are not common) may not show this accumulation.⁴

Choice of radiopharmaceutical. The first requirement of a radioisotope for bone scanning is that a high proportion of the administered dose be concentrated in bone and the remainder be excreted or at least be evenly distributed in lower concentrations throughout the body. The equilibration of the dose administered should be so rapid that scanning can be started soon after its administration, thus allowing the use of a short-lived radioisotope. The radioisotope administered also should be a gamma ray emitter with a high photon yield and no associated beta or electron emissions, in order to obtain a high counting rate with a small absorbed radiation dose to the organ being studied. The preferred energy of the isotope should be low enough to permit efficient collimation, yet not so low that there is excessive absorption of its energy by the body before it can be detected by the scanning instrument. In addition, the radioisotope selected should be available carrier-free or with a high specific activity, and the element should be of low toxicity. It seems unlikely that all these conditions can be met by any single isotope, and the radioisotopes used today for bone scans have been far from this ideal.

When strontium-85 became available, it was possible to carry out bone scanning with the ordinary commercial scanners. This radioisotope's 514 keV gamma ray is near the upper limits of efficient detection with such machines; however, its 65-day

half-li
main c
cal) re
partial
colon c
Cleans
V
fluorin
yttrium
radiois
enough
tion of
perform
strontiu
adminis
this als
Fluorin
tron. A
take adv
would st
To
pharmac
sought.

half-life allows the commercial preparation of sterile, pyrogen-free solutions. The main disadvantage of strontium-85 is that its long half-life (both physical and biological) results in a significant radiation dose to the patient. Also, since strontium-85 is partially excreted by the gastrointestinal tract, accumulation of the radioisotope in the colon often leads to misinterpreting the colon content as being a lesion in the pelvis. Cleansing enemas are therefore necessary prior to any scanning procedure.

Where local facilities for radioisotope production exist, strontium-87m and fluorine-18 can be used. Strontium-87m can also be obtained from an 80-hour yttrium-87 generator in the citrate or carbonate form. The short half-lives of these radioisotopes allow the administration of multimillicurie quantities which give high enough count rates for the detection of small lesions. However, the slow renal excretion of strontium-87m, coupled with its short half-life, results in the scans being performed when the blood and extracellular fluid contain high background levels of strontium-87m. The extremely short half-life of fluorine-18 (110 minutes) allows the administration of large doses, with associated low radiation dosage to the patient; but this also prevents it being shipped any great distance and limits its usefulness. Fluorine-18 is therefore available only to institutions located near a reactor or cyclotron. As suitable reactors are installed throughout the country, more hospitals could take advantage of this isotope for bone scanning. Transportation and cost problems would still exist and would still limit its general availability.

Technetium-99m polyphosphate. With the present disadvantages of the radio-pharmaceuticals now available for bone scanning, a more desirable agent has been sought. In 1971, Subramanian et al.⁶ introduced technetium-99m polyphosphate as a

short-lived radiopharmaceutical for skeletal imaging, and it has since become the most desirable radioisotope for imaging bone with the currently available scanning equipment. Its 140 keV gamma ray energy and 6-hour half-life make technetium-99m an ideal scanning agent. These physical characteristics permit the administration of millicurie dosages which greatly increase the counting rate and allow a shorter scanning time. They also make possible imaging on the same day of radiopharmaceutical administration. Suitable images can be obtained with either the standard scanner or the Anger scintillation camera. Technetium-99m polyphosphate is excreted by the kidneys, thus avoiding the background colon activity seen with strontium-85. All these advantages, plus the greatly diminished radiation exposure to the patient, make it the most desirable bone scanning agent available. The only disadvantage that is encountered with this radiopharmaceutical is interference from urine activity, especially bladder activity, in those patients unable to void prior to the scan (Figure 1).

The purpose of this study was to compare technetium-99m polyphosphate and strontium-85 for skeletal imaging in patients with metastatic disease.

II. MATERIALS AND METHODS

A series of 75 patients with known malignant disease was evaluated with both strontium-85 and technetium-99m polyphosphate bone scans. A dose of 10 mCi per patient was injected for the technetium-99m polyphosphate scans. Scans were obtained 3 to 4 hours following injection utilizing the rectilinear scanner (Ohio-Nuclear dual head scanner), multiprobe (Dynapix) scanner or Anger radioisotope camera. Bladder emptying was the only preparation utilized. With strontium-85, a dose of 100 μ Ci per patient was administered and the scans were obtained approximately 4 days

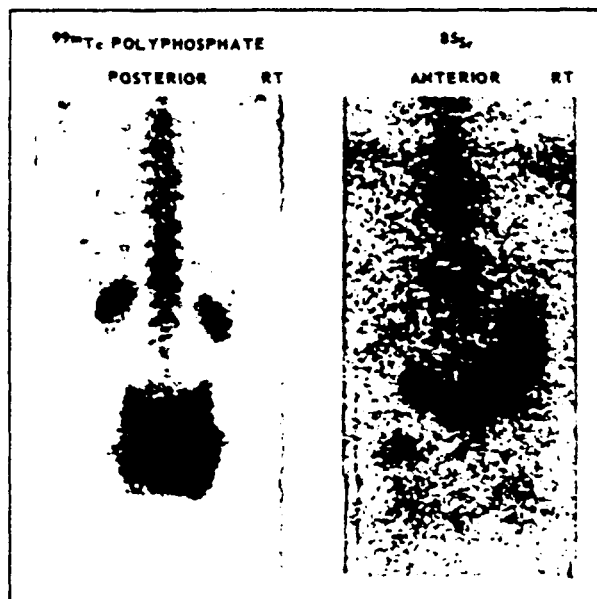


Figure 1. Technetium-99m polyphosphate and strontium-85 bone scans depicting the interference from bladder activity obtained with the technetium-99m polyphosphate agent and bowel activity with the strontium-85 agent

after administration, using only the dual head (Ohio-Nuclear) rectilinear scanner or multiprobe (Dynapix) scanner. Bowel cleansing was routinely employed. Areas of interest were scanned, as indicated, and contralateral areas were scanned when possible. With the low count rate obtained with the strontium-85 scans, due to the limited amount of radiopharmaceutical that could be used, each scan took approximately 1 hour. With the technetium-99m polyphosphate scan, the scans took only 15 to 20 minutes, due to the high count rates obtained with the millicurie-administered dose. The scans were always compared with routine x rays, if available, and when possible the same instrumentation was utilized with both radiopharmaceuticals in each patient. The interpretation of the scans was visual, and one area was always compared to another preferably in a similar region.

III. RESULTS AND DISCUSSION

Results of this study showed that more areas were visualized with technetium-99m polyphosphate scans than with strontium-85 scans (Figure 2). Thus, it was evident that our definition of a normal scan should be revised accordingly. Figure 3 demonstrates that uptake of technetium-99m polyphosphate is visualized well not only in the lumbar spine and pelvis, as with the strontium-85, but also in the ribs, individual vertebral bodies, the long bones, and skull. Hence, the comparison of similar regions during interpretation (i. e., right and left rib cage) is even more feasible with technetium-99m polyphosphate scans than with strontium-85 scans (Figure 4). Preliminary data from these 75 patients indicate that the technetium-99m polyphosphate bone scans will detect a greater number of lesions than the strontium-85 bone scanning agent in approximately 20 percent of the patients (Figure 5).

Scans obtained with both technetium-99m polyphosphate and strontium-85 were positive for pathologic changes prior to their demonstration in bone roentgenograms but were not specific for metastatic disease alone.⁷ This is depicted in Figure 6 which is a markedly positive scan, with technetium-99m polyphosphate, of a patient with Paget's disease confined to the skull. Difficulty in demonstrating disease in patients with marked destructive bone lesions (such as are seen in myeloma) was encountered with both technetium-99m polyphosphate and strontium-85. Anterior bone scans were found to be helpful in detecting disease in such areas as the sternum and pubic symphysis.

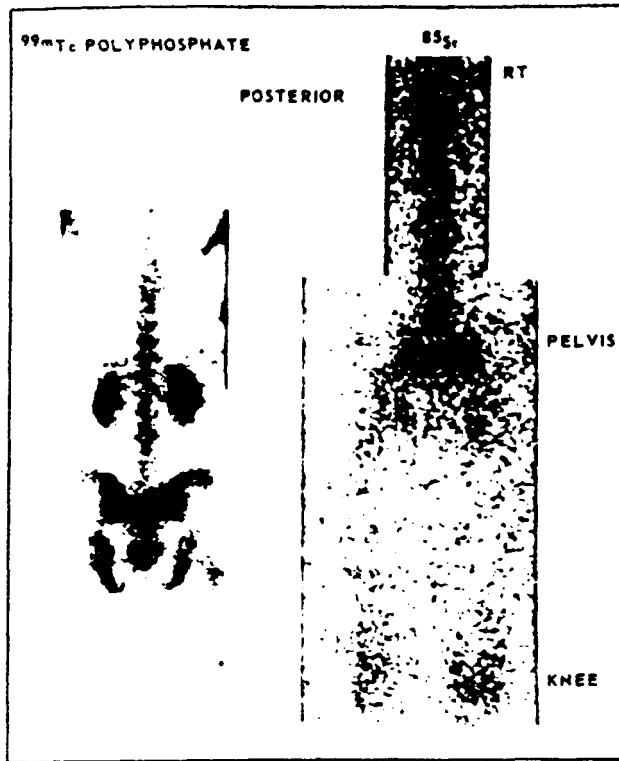
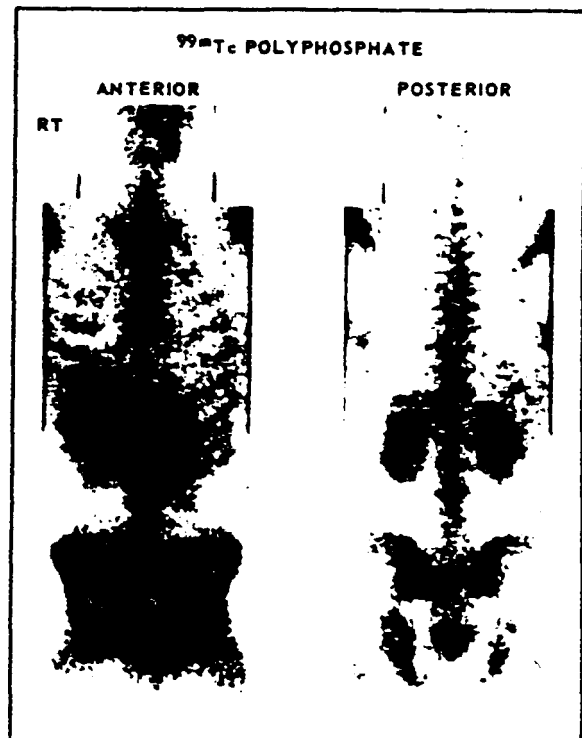


Figure 2.
Normal technetium-99m polyphosphate
and strontium-85 bone scans

Figure 3.
Anterior and posterior views in a normal
technetium-99m polyphosphate bone scan



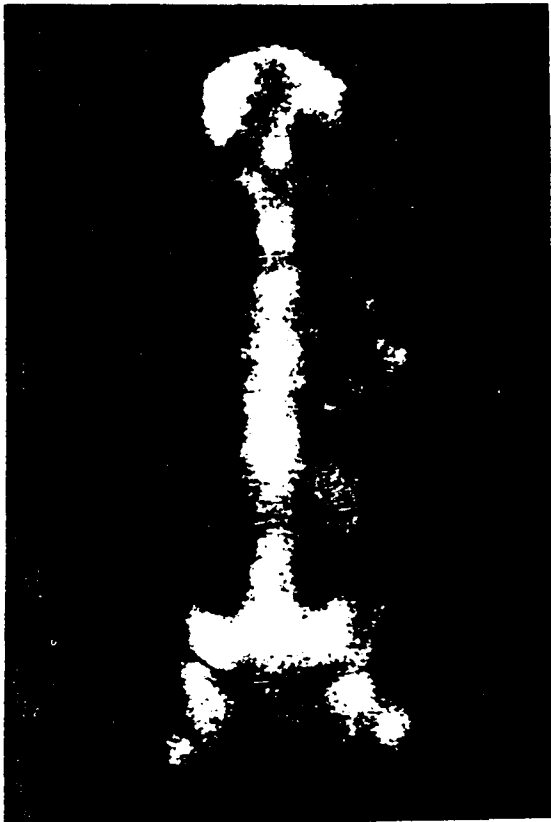



Figure 4.
Bone scan obtained with technetium-99m polyphosphate revealing multiple metastatic lesions in a patient with metastasis from carcinoma of the breast

Figure 5.
A technetium-99m polyphosphate (PP) bone scan and a strontium-85 bone scan obtained from a patient with metastatic lesions from carcinoma of the breast. The strontium-85 scan revealed none of the metastatic lesions whereas the technetium-99m polyphosphate scan revealed multiple lesions in the lumbar spine.



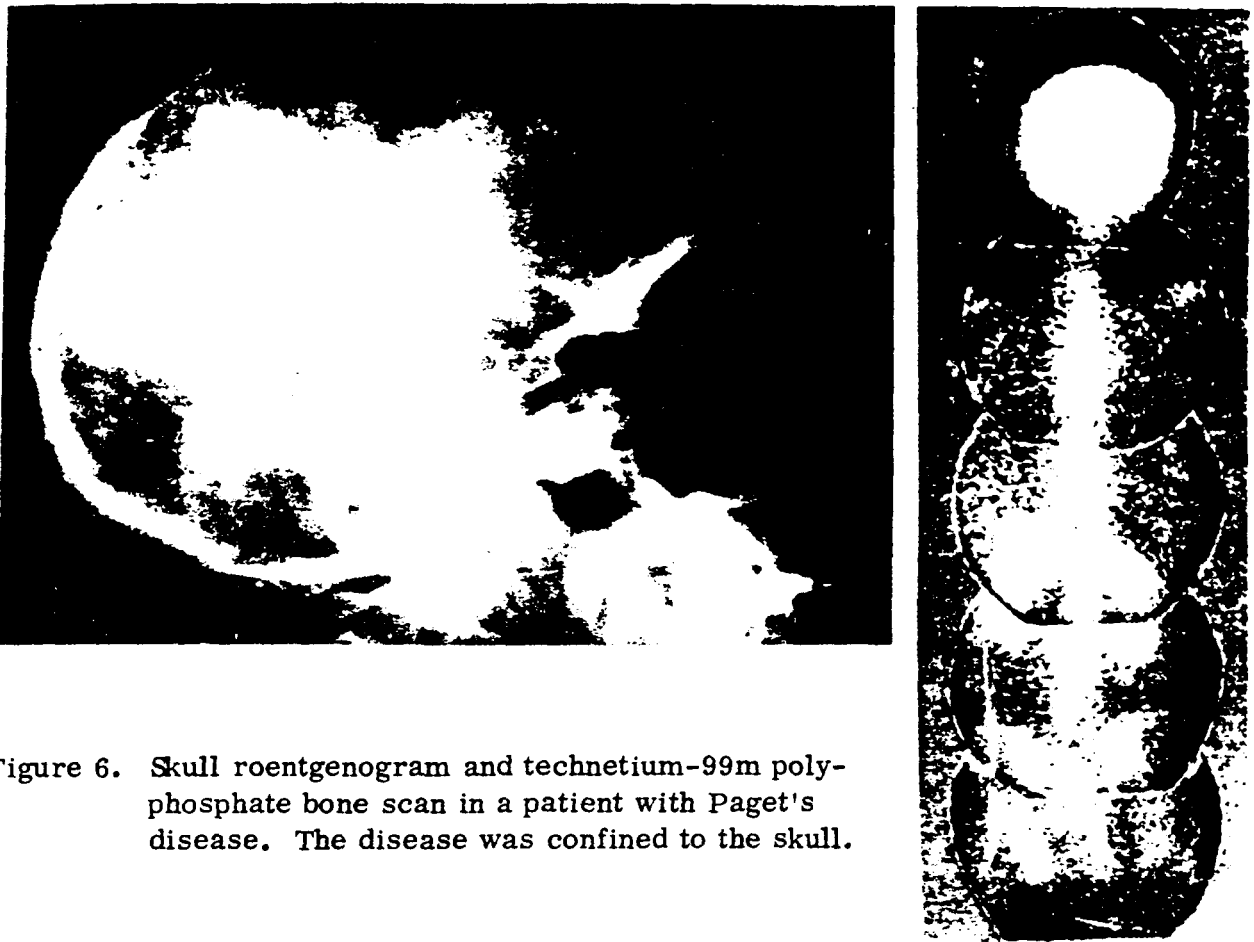


Figure 6. Skull roentgenogram and technetium-99m polyphosphate bone scan in a patient with Paget's disease. The disease was confined to the skull.

IV. SUMMARY

A new agent, technetium-99m polyphosphate, is now available for bone scanning. In comparing technetium-99m polyphosphate scans with strontium-85 scans, the following findings were noted: (a) a greater number of lesions were detected with the technetium-99m polyphosphate scans (approximately 20 percent of patients); (b) a greatly increased counting rate with shorter scanning times was available with the technetium-99m polyphosphate scans due to the higher dose that could be administered; (c) an ability to image on the day of administration of the dose was realized with the technetium-99m polyphosphate scan; (d) suitable imaging could be obtained by both the

camera and scanner with the technetium-99m polyphosphate scan, in contrast to being limited to the scanner with strontium-85; and (e) colon activity, as seen with strontium-85, was absent in technetium-99m scans; but increased bladder activity did occur, requiring voiding prior to obtaining each scan.

At present, it appears that the ideal physical characteristics of technetium-99m polyphosphate for scanning and its increased sensitivity for detecting bone lesions make it a far superior radiopharmaceutical for skeletal imaging than strontium-85.

- 1.
- 2.
- 3.
- 4.
- 5.
- 6.
- 7.

REFERENCES

1. Bauer, G. C. H. and Wendeberg, B. External counting of Ca^{47} and Sr^{85} in studies of localised skeletal lesions in man. *J. Bone Joint Surg.* 41-B:558-580, 1959.
2. Bland, W. H. *Nuclear Medicine*, 2nd ed., pp. 453-486. New York, N. Y., McGraw-Hill Book Company, 1971.
3. Fleming, W. H., McIlraith, J. D. and King, E. R. Photoscanning of bone lesions utilizing strontium 85. *Radiology* 77:635-636, 1961.
4. Freeman, L. M. and Blaurock, M. D., editors. *Radionuclide studies of the osseous structures*. *Seminars Nucl. Med.* 2(1):1-93, 1972.
5. Gynning, I., Langeland, P., Lindberg, S. and Waldskog, B. Localization with Sr^{85} of spinal metastases in mammary cancer and changes in uptake after hormone and roentgen therapy: a preliminary report. *Acta Radiol.* 55:119-128, 1961.
6. Subramanian, G., McAfee, J. G., Bell, E. G., Blair, R. J., O'Mara, R. E. and Ralston, P. H. $^{99\text{m}}\text{Tc}$ -labeled polyphosphate as a skeletal imaging agent. *Radiology* 102:701-704, 1972.
7. Treadwell, A. de G., Low-Beer, B. V. A., Friedell, H. L. and Lawrence, J. H. Metabolic studies on neoplasm of bone with the aid of radioactive strontium. *Am. J. Med. Sci.* 204:521-530, 1942.

DOCUMENT CONTROL DATA - R & D

(Security classification of title, body of abstract and indexing annotation must be entered when the overall report is classified)

1. ORIGINATING ACTIVITY (Corporate author) Armed Forces Radiobiology Research Institute Defense Nuclear Agency Bethesda, Maryland 20014		2a. REPORT SECURITY CLASSIFICATION UNCLASSIFIED	
		2b. GROUP N/A	
3. REPORT TITLE COMPARISON OF TECHNETIUM-99m POLYPHOSPHATE AND STRONTIUM-85 FOR SKELETAL IMAGING IN PATIENTS WITH METASTATIC DISEASE			
4. DESCRIPTIVE NOTES (Type of report and inclusive dates)			
5. AUTHOR(S) (First name, middle initial, last name) J. S. Stevenson and C. D. Maynard			
6. REPORT DATE June 1973		7a. TOTAL NO. OF PAGES 15	7b. NO. OF REFS 7
8a. CONTRACT OR GRANT NO.		9a. ORIGINATOR'S REPORT NUMBER(S) AFRRI SR73-8	
b. PROJECT NO NWED QAXM c. Task and Subtask C 906 d. Work Unit 06		9b. OTHER REPORT NO(S) (Any other numbers that may be assigned this report)	
10. DISTRIBUTION STATEMENT Approved for public release; distribution unlimited			
11. SUPPLEMENTARY NOTES		12. SPONSORING MILITARY ACTIVITY Director Defense Nuclear Agency Washington, D. C. 20305	
13. ABSTRACT <p>Tchnetium-99m polyphosphate has been recently introduced to replace strontium-85 as a short-lived radiopharmaceutical for skeletal imaging. Bone scans have been obtained with both strontium-85 and technetium-99m, to compare their relative efficacy, in a series of patients with known malignant disease. When possible, the same instrumentation was utilized with both radiopharmaceuticals in each patient. Data on approximately 75 patients indicate that the technetium-99m polyphosphate bone scans will detect a greater number of lesions than strontium-85, in approximately 20 percent of the patients. Other advantages of technetium-99m polyphosphate include: a greatly increased counting rate with shorter scanning time, the ability to image on the day of administration of the dose, suitability for imaging by either camera or scanner, absence of colon activity, and a greatly diminished radiation exposure to the patient. It is evident that technetium-99m polyphosphate is definitely superior to strontium-85 as a bone scanning agent.</p>			

UNCLASSIFIED

Security Classification

14. KEY WORDS	LINK A		LINK B		LINK C	
	ROLE	WT	ROLE	WT	ROLE	WT

UNCLASSIFIED

Security Classification