

**AFRI**  
**TECHNICAL**  
**NOTE**

AFRI  
LIBRARY

**DTL 74757B**  
**AFRI TN74-8**

DATE

[Redacted]

UNITED STATES GOVERNMENT

TECHNETIUM-99m DIPHOSPHONATE SCINTIGRAPHY TO DETECT  
EARLY AVASCULAR NECROSIS OF THE HIP

J. S. STEVENSON  
F. R. NELSON\*  
V. L. McMANAMAN

\* Orthopedic Department, National Naval Medical Center, Bethesda, Maryland

*Joe E. West*  
JOE E. WEST  
Lieutenant Colonel, USAF, VC  
Chairman  
Radiation Biology Department

*Myron I. Varon*  
MYRON I. VARON  
Captain MC USN  
Director

ARMED FORCES RADIOBIOLOGY RESEARCH INSTITUTE  
Defense Nuclear Agency  
Bethesda, Maryland

Approved for public release; distribution unlimited

## ACKNOWLEDGMENT

The authors are grateful to N. L. Fleming, J. K. Warrenfeltz, and M. E. Flynn for their technical assistance and to M. D. Sinclair for his invaluable assistance with data quantitation.

## TABLE OF CONTENTS

	Page
Absiract . . . . .	iii
I. Introduction . . . . .	1
II. Materials and Methods . . . . .	2
III. Results . . . . .	3
IV. Discussion . . . . .	5
References . . . . .	7

## LIST OF FIGURES

Figure 1. Routine static images utilizing high resolution collimation and tomographic "cuts" of each hip area . . . . .	3
Figure 2. Computer cathode-ray tube images of both the right hip and left hip and a histogram . . . . .	4

## ABSTRACT

Ten National Naval Medical Center patients ages 20 to 62 and selected by history as having a high probability of early aseptic necrosis of the hip received bilateral tomographic hip technetium scans. The technetium-99m on a sodium diphosphonate carrier was injected between 2 and 3 hours prior to the scanning procedure. The gamma camera was centered over the hip, and tomographic "cuts" were made to approximately 500,000 counts each. The urinary bladder contained the greatest activity in most cases which usually required the patient to void prior to the scan. Once the tomographic level of interest was ascertained, it was used identically for both hips. The data were then processed on a MED-II computer. Of the 10 studies, there were four true positives, four true negatives, and one each false negative and false positive. Although this series of patients is too small to draw any definite conclusions as to the accuracy of the method, it is apparent that it is a potentially effective means of detecting the presence of aseptic necrosis prior to radiographic changes.

## I. INTRODUCTION

Various techniques, including angiography, venography, oxygen tension determinations, intramedullary pressure measurements, as well as the use of radioactive (fluorine-18,<sup>2</sup> phosphorus-32<sup>1,3</sup>) tracers, have been used to detect and assess avascular necrosis of the femoral head.<sup>2</sup> None of these techniques are presently being used routinely, since either they have proven difficult and cumbersome to perform requiring the use of an operating room or the results have been inconclusive.<sup>2</sup>

A previous report<sup>2</sup> has shown with fluorine-18 that in the first weeks of avascularity there is decreased uptake of the radiopharmaceutical in the region of avascular aseptic necrosis. Subsequently, however, and until the area is totally revascularized, there appears to be an increased uptake of the radiopharmaceutical in the areas of increased bone accretion. This appears to be due to the patient's response in attempting to revascularize the area. The increased vascularity initially appears to be located around the periphery of the lesion and appears as a "hot" area during the healing period. Once the lesion has completely revascularized, however, the scans return to a normal pattern.<sup>2</sup>

This report is concerned with the use of a new bone scanning radiopharmaceutical, technetium-99m diphosphonate, and the high performance Nuclear-Chicago scintillation camera with tomographic characteristics to diagnose and follow patients with avascular disorders of the hip. Tomographic capabilities should be adequate to improve images of technetium-99m diphosphonate bone scans by discriminating against radiopharmaceutical accumulations in the surrounding tissues.

A study was performed in 10 National Naval Medical Center (NNMC) patients selected by history (hip pain with normal roentgenograms of the symptomatic hip) as associated with a high probability of having early avascular necrosis of the hip. Their ages ranged from 20 to 62. Six of the ten patients were studied within 1 week of their initial symptoms, the other four patients were studied 3-4 weeks following their initial symptoms of hip pain.

## II. MATERIALS AND METHODS

All patients treated were administered the radiopharmaceutical at the Nuclear Medicine Branch, Radiology Department, NNMC, and transported to the AFRI for the scanning procedure. Technetium-99m diphosphonate was administered intravenously as a single bolus in a dose of 15 mCi between 2 and 3 hours prior to the scanning procedure. The scanning procedure consisted of static images and tomography "cuts" over both hips with the gamma camera head and high resolution collimator centered over both hips (Figure 1). A total of 500,000 counts per image were accumulated in obtaining each static image. Four revolutions, approximating 500,000 counts each, were used to obtain the tomography cuts. The urinary bladder contained the greatest activity in most cases, and this required the patient to void prior to the scan. In addition, shielding material was placed over the bladder to block out its activity.

The tomographic level of interest was ascertained with serial cuts at various 1-cm levels to obtain a base line. Once the tomographic level of interest was determined, it was used identically for both hips. The data were then acquired and stored on videotape and analyzed on a MED-II computer. The computer equipment allows for the projection of a picture on a 64 x 64 point grid, giving a total of 4096 points, from which a mathematical histogram computation can be performed for areas of interest (Figure 2).

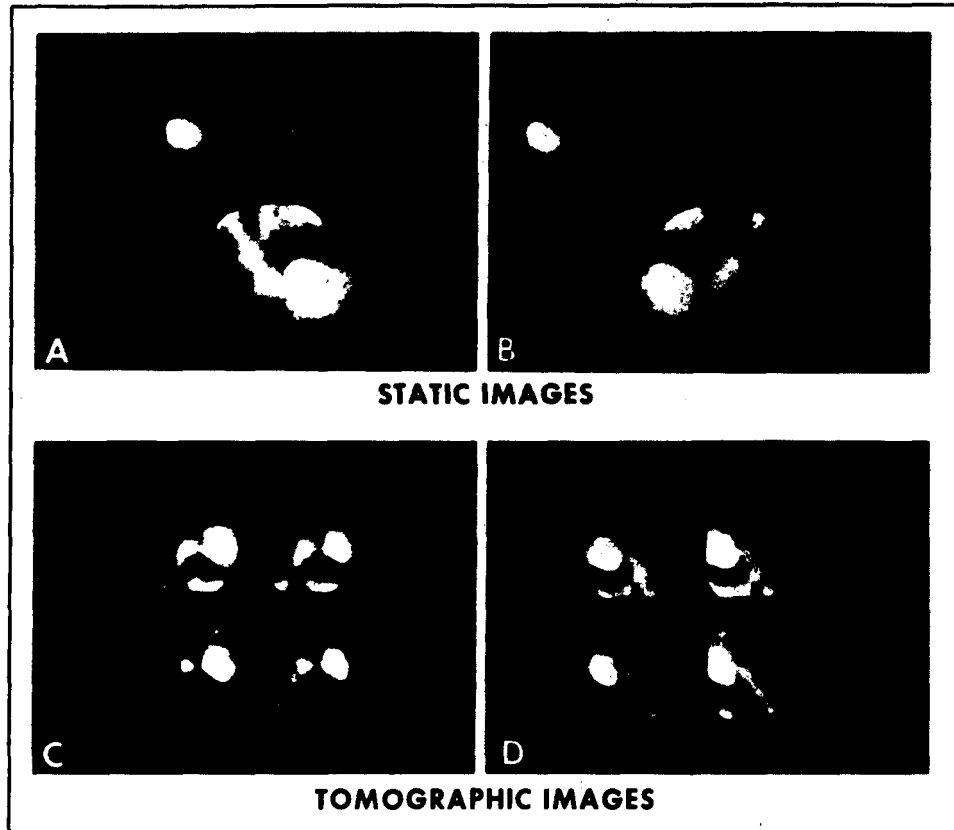


Figure 1. Routine static images (A and B) were obtained utilizing the high resolution collimation. This was followed by tomographic "cuts" (C and D) of each hip area. The negative defect in A and C represents early avascular necrosis (study made less than 1 week after symptoms occurred).

### III. RESULTS

Of the 10 patient studies, there were four true positives, i. e., diagnosis of avascular necrosis of the femoral head confirmed by x rays months later, four true negatives, one false negative and one false positive, using the diagnostic criteria of D'Ambrosia et al.<sup>2</sup>



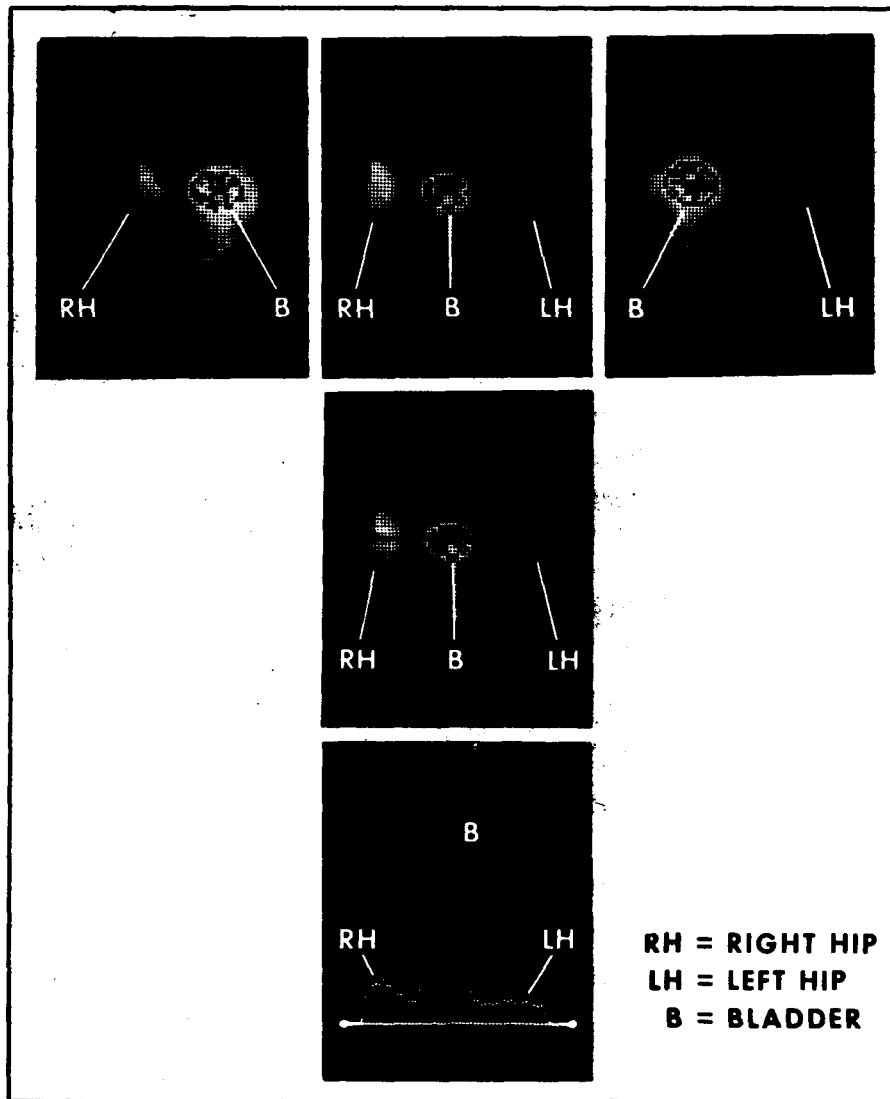


Figure 2. Computer cathode-ray tube images of both the right hip and left hip were obtained. An area of interest was chosen (linear black line in middle figure) and a histogram generated (lower figure) revealing decreased activity in the LH area as compared to the RH (the center peak on the histogram represents bladder activity) consistent with RH avascularity and the patient's response in attempting to revascularize the area.

#### IV. DISCUSSION

Although this series of patients is too small to draw any definite conclusion as to the accuracy of the method used, it is apparent that it is a potentially effective means of detecting aseptic necrosis of the hip.

Studies of  $^{32}\text{P}$  uptake in avascular necrosis of the femoral head appear to be of prognostic value in two-thirds of Boyd and Calandruccio's<sup>1</sup> group of 130 patients with displaced fractures of the neck of the femur. If the data from these studies with  $^{32}\text{P}$  had been used as the deciding factor as to whether a prosthesis should have been surgically inserted as the primary therapeutic measure, an actual or irreversible error would have occurred in approximately 10 percent of their patients.<sup>1</sup>

Pain is the main symptom associated with avascular necrosis; but the definitive diagnostic findings of collapse of the articular surface of the femoral head and relative increase in density of the involved bone on roentgenograms are usually not observed for 9 to 24 months after the insult.<sup>1</sup>

One of the main advantages to this nuclear imaging technique is that it is a simple, atraumatic procedure and is suitable for repeated serial follow-up studies of patients with avascular bone disorders. Nuclear bone scanning radiopharmaceuticals of the phosphate compounds are also being used to assess other avascular conditions of bones. It is felt that this technique can be used to evaluate conditions including subcapital fractures of the femoral head, Legg-Calvé-Perthes disease, dislocated hip, osteochondritis dissecans involving the elbow and knee, and in avascular conditions of the carpal bones, especially the navicular, lunate as well as the tarsal bones, especially the talus and metatarsal heads. It is hoped that the data obtained from the

computer analyses will allow quantitation of the bone accretion rate around the area of avascular necrosis, as well as the determination of the rate of revascularization in the area in question. Further research in this area will hopefully continue to yield fruitful results, especially in the capability to predict those areas of avascular necrosis which will progress to complete bone healing and those which will not.

## REFERENCES

1. Boyd, H. B. and Calandruccio, R. A. Further observations on the use of radioactive phosphorus ( $P^{32}$ ) to determine the viability of the head of the femur. J. Bone Joint Surg. 45-A:445-460, 1963.
2. D'Ambrosia, R. D., Riggins, R. S. and DeNardo, G.  $^{18}F$  scintigraphy in diagnosis and management of avascular necrosis bone disorders. Surg. Forum 24: 473-474, 1973.
3. Tucker, F. R. The use of radioactive phosphorus in the diagnosis of avascular necrosis of the femoral head. J. Bone Joint Surg. 32-B:100-107, 1950.

DOCUMENT CONTROL DATA - R & D

(Security classification of title, body of abstract and indexing annotation must be entered when the overall report is classified)

1. ORIGINATING ACTIVITY (Corporate author) Armed Forces Radiobiology Research Institute Defense Nuclear Agency Bethesda, Maryland 20014		2a. REPORT SECURITY CLASSIFICATION UNCLASSIFIED	
		2b. GROUP N/A	
3. REPORT TITLE TECHNETIUM-99m DIPHOSPHONATE SCINTIGRAPHY TO DETECT EARLY AVASCULAR NECROSIS OF THE HIP			
4. DESCRIPTIVE NOTES (Type of report and inclusive dates)			
5. AUTHOR(S) (First name, middle initial, last name) J. S. Stevenson, F. R. Nelson and V. L. McManaman			
6. REPORT DATE July 1974		7a. TOTAL NO. OF PAGES 10	7b. NO. OF REFS 3
8a. CONTRACT OR GRANT NO.		9a. ORIGINATOR'S REPORT NUMBER(S) AFRRI TN74-6	
b. PROJECT NO. NWED QAXM			
c. Task and Subtask C 911		9b. OTHER REPORT NO(S) (Any other numbers that may be assigned this report)	
d. Work Unit 02			
10. DISTRIBUTION STATEMENT Approved for public release; distribution unlimited			
11. SUPPLEMENTARY NOTES		12. SPONSORING MILITARY ACTIVITY Director Defense Nuclear Agency Washington, D. C. 20305	
13. ABSTRACT <p>Ten National Naval Medical Center patients ages 20 to 62 and selected by history as having a high probability of early aseptic necrosis of the hip received bilateral tomographic hip technetium scans. The technetium-99m on a sodium diphosphonate carrier was injected between 2 and 3 hours prior to the scanning procedure. The gamma camera was centered over the hip, and tomographic "cuts" were made to approximately 500,000 counts each. The urinary bladder contained the greatest activity in most cases which usually required the patient to void prior to the scan. Once the tomographic level of interest was ascertained, it was used identically for both hips. The data were then processed on a MED-II computer. Of the 10 studies, there were four true positives, four true negatives, and one each false negative and false positive. Although this series of patients is too small to draw any definite conclusions as to the accuracy of the method, it is apparent that it is a potentially effective means of detecting the presence of aseptic necrosis prior to radiographic changes.</p>			

**UNCLASSIFIED**  
Security Classification

14. KEY WORDS	LINK A		LINK B		LINK C	
	ROLE	WT	ROLE	WT	ROLE	WT

**UNCLASSIFIED**  
Security Classification